

Managing horse wounds either presenting or not with exuberant granulation tissue using an innovative wound dressing: A retrospective non-controlled study

Fiorella Carnevali^{1,*}, Marco Argentieri², Graziano Ippedico², Carlo Alberto Minniti³, Luigi Amodio², Luigi Mellano⁴, Stephen Andrew van der Esch¹

¹Enea CR Casaccia, Via Anguillarese 301, 00123 Rome Italy

²Veterinary Infirmery Service of the Mounted Regiment of Carabinieri, Viale Tor di Quinto 155, 00191, Rome Italy

³Veterinary Service of Corazzieri Regiment of the President of the Italian Republic, via XX settembre, 00196 Roma

⁴Military Veterinary Hospital, Via Montelibrettense snc, 00010 Montelibretti, Italy

Email address

fiorella.carnevali@enea.it (F. Carnevali), marco.argentieri@carabinieri.it (M. Argentieri), graziano.ippedico@carabinieri.it (G. Ippedico), wethorse@libero.it (C. A. Minniti), luigi.amodio@carabinieri.it (L. Amodio), luigi.mellano@esercito.difesa.it (L. Mellano), stephen.vanderesch@enea.it (S. A. V. D. Esch)

To cite this article

Fiorella Carnevali, Marco Argentieri, Graziano Ippedico, Carlo Alberto Minniti, Luigi Amodio, Luigi Mellano, Stephen Andrew van der Esch. Managing Horse Wounds Either Presenting or not with Exuberant Granulation Tissue Using an Innovative Wound Dressing: A Retrospective Non-Controlled Study. *Journal of Animal and Veterinary Sciences*. Vol. 1, No. 2, 2014, pp. 6-16.

Abstract

Reasons for performing study: Because we used a different innovative protocol for treating equine traumatic wounds, it was decided to analyse retrospectively all the cases treated during the years 2005-2012. Objective: Evaluate the healing performances of traumatic horse wounds, either presenting or not with exuberant granulation tissue (EGT) or exposed bone, using an innovative plant-derived wound dressing and restricting the systemic antibiotic administration only to the first week after trauma. Methods: A retrospective analysis was conducted of all horses (n = 57) presenting with accidental wounds and treated with a plant-derived wound dressing. Classification of Wounds using COW score (Simple Wounds –SW- or Wounds presenting with Exuberant Granulation Tissue – EGT-W), Time To Heal (days), Epithelialisation Rate (cm/days), Health Of Wounds score, Time of First Epithelium appearance (TFE), Cosmetic Aspect of the final Scar (CAS), ease of handling, pain and complications were recorded and evaluated. Results: COW score determined 32 Simple Wounds (SW) with mean size varying from 12,72±6.48 cm² (< 25 cm²), 50,76± 14,20 cm² (25 and 100 cm²) to 310,023±132,(> 100cm²) and 25 EGT-Wounds (EGT-W) with mean size varying from 12,90±4,51cm² (<25 cm²) to 62,76±26,55 cm² (25 and 100 cm²). The SW healed faster than the EGT-W showing significant differences in the evaluated parameters (58,06±39,44 vs 79±54,32 days) (SW=0,14±0,06 vs EGT-W 0,0742±0,0342 cm/day) and in the TFE (of 7 vs of 18 days). CAS showed no significant differences between SW and EGT-W both presenting high quality of final scar. The dressing was able to keep the EGT formation under control without using surgical resection. Conclusions: This retrospective non-controlled analysis confirmed that equine wound complicated by the EGT have a lower healing performance but the EGT formation can be kept under control with a high quality of final scar. The treatment is simple to use and safe; it enables to reduce the intake of antibiotic and consequently limiting the risk of onset of antibiotic/antimicrobial resistance.

Keywords

Horse Wound Healing, Exuberant Granulation Tissue, Proud Flesh, Keloid, Hypergranulation, Primary Dressing

1. Introduction

Horses are predisposed to trauma wounds that can be labour intensive and expensive to manage. Wounds localized at the trunk region are less problematic and heal at a faster rate than wounds located at the distal aspect of the limb [1]. In the horse, complications such as wound infection, formation of exuberant granulation tissue (EGT) and hypertrophic scarring are frequent [2] especially at the distal aspect of the limb [3]. The EGT or “Proud Flesh” is considered similar to the keloid of the human skin [3,4] and, together with wound contamination/infection [3], is currently the most complicated aspect of wound management in equine.

The pathophysiology of excessive fibroplasia in equine lower limb wounds is poorly understood. Disregulation of fibroblast growth [5], decreased rates of contraction [6,7], microvascular occlusion [4], disregulated apoptotic process by hypoxia [4], changes in the expression of the TGF- β 1 [8,9], inefficient inflammatory response to trauma [10], disparity between the synthesis and degradation of collagen [11], down-regulation of specific gene expression [12] and lower oxygen saturation values of the equine limb compared to the body [4] may be involved. The major factors which seem to play an important role in promoting EGT formation are wound location [3,14] fully-occlusive, semi-occlusive or pressure bandaging [1,2,3,6,14,16,17,18,19], with the exception of silicone gel dressing [20], but not body size (height and weight) [21,22] contrary to what reports [23]. It has been demonstrated that the predisposition of equine to EGT formation is strongly influenced by genes and it is also present in miniature Caspian horses where height and weight are less or similar to ponies [21,22].

Once formed and protruding over the wound margins, the EGT impairs epithelialisation and wound contraction [3,19,24] and predisposes the wound to infection and further trauma [17]. According to Theoret and Wilmink 2008 [3] the best current therapy remains surgical excision of the protruding tissue [3,25] whereas topical applications of corticosteroids [3,13,26] and/or caustic agents [3,13,26] are not recommended and must be avoided as much as possible [3,26].

Numerous treatments have been advocated for promoting healthy healing and/or prevention of the EGT in horses, but the majority of these have failed to demonstrate a beneficial effect on equine wound healing [4, 8, 9,10,18,20,27] even if the same were proven effective on species other than equine [29]

The second problematic aspect of wound healing in horses is infection, which strongly impairs the healing process [1,30]. This justifies the use of antiseptics/antimicrobials on EGT wounds showing signs of chronic inflammation related to bacterial contamination [30]. This is partially due to the belief that the risk of infection is worse than the cytotoxic effect of antimicrobials on the wound surface despite reports that the use of antimicrobials was not effective in increasing the healing rate compared to untreated controls, either presenting with or

without EGT formation [19]. It must be noted that a recurrent therapeutic mistake made in human wound management (extensive topical use of antiseptics/antimicrobials on open wounds during the proliferative phase in the absence of clinical signs of infection [14, 31, 32] is also replicated in veterinary.

In the light of the present literature, many authors agree that no single dressing for every stage of all types of wounds in horse wound management is currently available, showing that an all-encompassing and effective protocol for preventing or treating the EGT is still lacking. A dressing appropriate during the inflammatory phase, should be avoided or used only intermittently during the proliferative phase [3,27,30,33]. Consequently, each single practitioner develops his/her own protocol for the treatment of the EGT in equine wound management based on a sort of “play it by ear” approach in which their own clinical judgement helps the practitioner determine which dressing to use at each stage of the treatment process.

Research on natural substances at ENEA Research Centre, Italy, has led to the formulation of a novel innovative primary dressing for wound management both in human (1 Primary Wound Dressing[®]) and veterinary medicine (named "one Vet" for the Italian market) licensed to Phytoceuticals Ltd Zurich. The device, invented for solving the wound's myiasigenic infestation [34], demonstrated biocide, repellent and significant properties which support each phase of the healing process [34,35,36,37]. It removes the need to use antimicrobials/disinfectants because of its combination of saturated, mono and poly-unsaturated Free Fatty Acids (FFAs), well known to possess antimicrobial properties [38]. The FFAs represent the main defensive barrier of the intact mammalian skin against infection, selected by evolutionary forces in such a manner that it seems relatively unlikely that resistant bacterial strains would arise [38]. Clinical data obtained, using this innovative device, strengthened and confirmed the antimicrobial activity of the oily formulation for managing second intention wound healing [34,35,36,37].

The aim of this retrospective non-controlled analysis is to refer about clinical results obtained treating accidental horse wounds healed by secondary intention, including wounds presenting with EGT and/or exposed bone, using the innovative plant derived device as primary wound dressing without combining it with any other topical disinfectant/antimicrobial devices and/or systemic antibiotic administration and surgical procedures such as EGT resection.

2. Materials and Methods

2.1. Animals

A retrospective non-controlled analysis was carried out on all horses presenting with trauma wounds (n=57) located on

Table 1. Abbreviations: Breed: IH= Iris Hunter, IC= Italian Crossbred, M=Maremmano, SAA=Sardinian Anglo-Arab, AP= Appaloosa, TB= Thoroughbred, HF= Haflinger, AC= Argentin Criollo, AA: Anglo Arabian, DW= Dutch Warmblood. Sex: G= Gelding, M= Mare, F= Fowl, S= Stallion. IAR: Involved Anatomic Region(s), H= Head, T= Trunk, PL= Proximal Limb, DL= Distal Limb, EXB= Exposed Bone. IWA= Initial Wound Area . COW= Classification Of Wounds score. WG=Wound Group: SW= Simple Wound, EGT-W= Exuberant Granulation Tissue Wound. TFE= Time of First evidence of Epithelium. SER= Stashak Epithelialization Rate. TTH= Time To Heal. CAS= Cosmetic Aspect of Scar.

Wound N°	Race	Weight Kg	Sex	IAR	IWA cm2	COW	Wound Group	TFE (days)	SER (cm/day)	TTH (days)	Bandage	CAS
W1	IH	700	G	T	4,09	0	SW	7	0,0963	21	NO	0
W2	IC	550	G	PL	5,04	2	SW	15	0,1069	21	NO	0
W3	IH	700	G	T	6,77	0	SW	7	0,1239	21	NO	0
W4	IC	150	F	T	15,26	0	SW	7	0,1860	21	NO	0
W5	IC	550	G	DL	17,25	1	SW	15	0,0799	52	NO	0
W6	M	600	G	PL	18,1	0	SW	7	0,1636	26	NO	0
W7	SAA	550	M	DL	20,03	0	SW	15	0,2356	19	NO	0
W8	IC	550	S	DL	24,27	0	SW	7	0,0684	72	NO	2
W9	IC	550	G	DL	37,65	0	SW	28	0,0548	112	NO	1
W10	AP	150	F	T	37,75	0	SW	7	0,1755	35	NO	0
W11	IC	550	M	PL	40,86	0	SW	15	0,1937	33	NO	0
W12	TB	600	G	PL	41,62	1	SW	7	0,1152	56	NO	0
W13	SAA	550	M	DL	47,31	0	SW	15	0,2645	26	NO	0
W14	IC	150	F	H	61,66	0	SW	7	0,1870	42	NO	0
W15	IC	550	M	T	64,79	0	SW	7	0,1872	43	NO	0
W16	IC	550	G	PL	74,43	0	SW	7	0,1052	82	NO	0
W17	M	600	M	PL	190	0	SW	21	0,1745	79	NO	0
W18	IC	550	M	T	213,9	0	SW	7	0,1625	90	NO	0
W19	M	600	M	PL	218,48	0	SW	15	0,0754	196	NO	0
W20	IC	150	F	T	296,58	0	SW	15	0,3021	57	NO	0
W21	IC	150	F	PL	427,65	1	SW	21	0,1846	112	NO	0
W22	IC	150	F	T	513,53	0	SW	21	0,2518	90	NO	0
W23	SAA	600	G	T	18,27	0	SW	7	0,0509	84	NO	0
W24	IC	550	M	H	ND	0	SW	7	ND	7	NO	0
W25	M	600	G	H	ND	0	SW	7	ND	71	NO	0
W26	AC	450	G	PL	ND	0	SW	21	ND	90	NO	0
W27	IC	550	G	H	ND	0	SW	15	ND	75	NO	0
W28	HF	350	G	DL	14,56	0	SW	7	0,1363	28	NO	1
W29	SAA	550	G	DL	11,1	0	SW	15	0,0775	43	NO	0
W30	AA	500	M	DL	7,43	0	SW	15	0,0278	98	NO	2
W31	IC	550	M	DL	4,49	0	SW	7	0,1009	21	NO	0
W32	IC	550	M	DL	11,44	0	SW	7	0,0966	35	NO	0
W33	IC	550	G	PL	9,16	3	EGT-W	21	0,0865	35	NO	0
W34	IC	550	M	DL	11,29	3	EGT-W	7	0,0589	57	NO	2
W35	IC	550	M	PL	11,36	3	EGT-W	15	0,0963	35	NO	1
W36	IC	100	F	DL	11,44	3	EGT-W	15	0,0546	62	NO	0
W37	IC	550	M	DL	16,46	3	EGT-W	15	0,1623	25	NO	ND
W38	IC	450	M	PL	19,75	3	EGT-W	21	0,1270	35	NO	0
W39	DW	740	G	DL	42,55	3	EGT-W	15	0,0271	241	NO	2
W40	DW	740	G	DL	99,62	3	EGT-W	15	0,0475	210	NO	2
W41	SAA	500	G	DL	ND	3	EGT-W	7	ND	21	NO	1
W42	IC	550	M	DL	5,65	3	EGT-W	15	0,0566	42	Yes	0
W43	IC	550	M	DL	7,38	3	EGT-W	21	0,0679	40	Yes	0
W44	IC	550	M	DL	9,32	4	EGT-W	15	0,0872	35	Yes	0
W45	IH	700	G	DL	10,11	3	EGT-W	15	0,0292	109	Yes	0
W46	IC	550	M	DL	10,66	3	EGT-W	21	0,1256	26	Yes	0
W47	SAA	450	M	DL	11,19	3	EGT-W	21	0,0398	84	Yes	1
W48	TB	550	G	DL	13,5	4	EGT-W	21	0,0510	72	Yes	1
W49	IH	700	G	DL	14,09	4	EGT-W	28	0,0315	119	Yes	0
W50	IC	550	G	DL	17,38	4	EGT-W	15	0,0719	58	Yes	0
W51	IH	700	G	DL	18,87	3	EGT-W	15	0,0530	82	Yes	0
W52	TB	500	M	DL	21,61	3	EGT-W	21	0,1192	39	Yes	0
W53	IH	700	G	DI	30,58	4	EGT-W	21	0,0608	91	Yes	0
W54	IC	550	G	DI)	40,17	4	EGT-W	21	0,0792	80	Yes	0
W55	IC	150	F	DL-EXB	58,51	4	EGT-W	35	0,0632	121	Yes	0
W56	TB	500	M	DL-EXB	83,75	4	EGT-W	21	0,0934	98	Yes	0
W57	IC	550	M	DL-EXB	84,16	4	EGT-W	21	0,0917	100	Yes	0

different anatomic parts presented over the years 2005-2012 at three different Veterinary Services: the Veterinary Service of the Carabinieri Mounted Regiment, the Infirmary of the Corazzieri Regiment and the Military Veterinary Hospital. Severely wounded horses received systemic antibiotic therapy according to body size or wound severity only during the first week after trauma. In Table 1 details of the individual animals and relative wounds are listed.

2.2. Wounds

All the wounds reviewed (n= 57) could only be healed by secondary intention, including those which developed surgical suture dehiscence. A Classification Of Wounds score system (COW) [20,28] was adopted in order to determine whether the wounds were Simple Wounds (SW) or Exuberant Granulation Tissue Wounds (EGT-W). The COW score was first assessed at the 15th day from injury [20] or first visit, it was repeated at the 30th, 60th, 90th and 120th day. The COW score was determined by the total score of: Quality of Granulation Tissue (QGT: 0= smooth, 1= rough (clefts, depressions)), Colour of Granulation Tissue (CGT: 0= red healthy granulation tissue, 1= pink or necrotic tissue), Protuberance of Granulation Tissue from the skin level (PGT: 0= none, 1= mild and 2= marked). The maximum value of 4 was calculated on the basis of the weight of each criterion as follows: QGT= 25%, CGT= 25% and PGT= 50%. All wounds scoring ≤ 2 were classified as simple wounds (SW) while those scoring >2 were classified as EGT wounds (EGT-W) (see Table 1).

2.3. Device

The patented device used is a plant derived product containing oily extracts from *Azadirachta indica* (A Juss) and *Hypericum perforatum* (L.) registered as medical device for topical application in human wound care "1 Primary Wound Dressing®" and "one VET" for the Italian veterinary market. The device used was patented by ENEA and Phytoceuticals Ltd, Zurich (WO-2006013607) and it is commercialized by Phytoceutical Ltd, Zurich.

2.4. Treatment

The protocol involved the sole use of the plant derived device applied daily on the wound surface as a primary wound dressing from the first visit, till complete epithelialisation. In the cases in which the EGT protruded the skin level more than 0,5 cm and bandage could be held in place, a permanent semi-occlusive pressure bandage was applied using non sterile cotton gauzes and cohesive elastic wrap (bandaged: EGT-WB sub groups n=16) (not bandaged: EGT-WNB sub group n= 10) (see Table 1). Wounds were previously rinsed with saline/ringer solution and, if necessary, surgical debridement was performed within the first week after trauma. Most of the wounds were treated immediately after the traumatic event (51/57), of the remaining six wounds (6/57), 5 (W8, W18, W29, W34, W51), were recruited because presenting

poor healing progress using conventional treatments. W54 was first assessed when a fibrotic exuberant granulation tissue, exceeding the skin level by 3,77 cm, had already formed, the EGT was surgically removed (once) under general anesthesia. Evaluation and calculation of healing parameters of these cases started at the first application of the protocol and then treated as all the other cases.

2.5. Assessment of Wound Healing

Parameters as Initial Wound Area (IWA) (cm²) and Time to Heal (TTH) (days), defined as the time from the first visit till complete epithelialisation, were recorded and used for the Stashak's calculation of Epithelialisation Rate (SER: cm/day) defined as the ratio between square root of IWA and TTH ($\sqrt{IWA/TTH}$) [1]. For recording the IWA the aspect of the wound surface and its dimension were photographed using a digital camera inserting a two dimensional calibration scale in the view proximal to the wound. Where wounds lay along the body contour they were traced on clear plastic film, then photographed on scaled graph paper and processed as digital images. The wound areas (cm²) were calculated using commercially available software (CAD-CAM Autodesk MAP 3D, 2005). For evaluating the health of the wound time course the Health Of Wound (HOW) score was adopted [28]. It is defined as the total score of Presence of Inflammatory Exudate (PIE: 0: none; 1: thin film; 2: thick crust over the wound surface); Perilesional Skin Appearance (PSA: 0: no hyperaemia or swelling; 1: mild hyperaemia and swelling; 2: strong hyperaemia and swelling); Appearance of Granulation Tissue (AGT: 0: red and regular; 1: pink and irregular, 2: dark and irregular). A maximum value of 6 was calculated on the basis of the weight of each criterion as follows: PIE = 33,3%, PSA = 33,3% and AGT = 33,3%. All wounds scoring <3 were considered healthy, while all wounds scoring ≥ 3 were classified as inflamed or complicated. The HOW score evaluation was performed starting at the time of injury or the first visit (Day 0) and then at the 7th, 15th, 30th, 60th and 90th Day from injury, depending on the course of healing of each wound. Time to First evidence of Epithelium appearance (TFE) (days) was determined by the first appearance of epithelialisation margins detected at weekly intervals. Cosmetic Aspect of the final Scar (CAS) was determined at wound closure as: 0= excellent (no evidence of scarring and presence of adnexa), 1= good (small amount of scar tissue and some wound area deprived of adnexa) and 3= excessive scar (hypertrophic protruding scar and absence of adnexa) [39].

2.6. Statistical Analysis

The TTH and SER were analysed by means of the t test. The HOW score was analysed by means of the Z-test with the Yates' correction. The TFE was analyzed using the Median test and the CAS by means of the Kolmogorov-Smirnov test for two independent samples.

3. Results

Based on the COW score performed at the 15th day 32/57 wounds were assessed as Simple Wounds (SW group) while 25/57 as complicated by EGT formation (EGT-W group)(see Table 1). All the simple wounds (SW) were located at the head or trunk while all the EGT wounds (EGT-W) at the distal aspect of the limbs

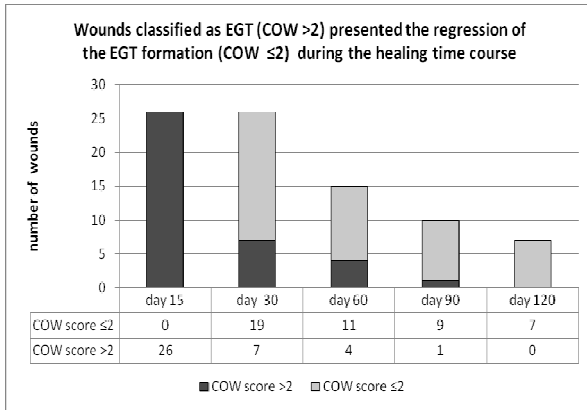


Figure 1. Histogram of number of wounds classified as Exuberant Granulation Tissue Wounds at the 15th day after injury by COW scoring system (EGT-W group) (COW score >2) which underwent the EGT regression during the healing course (COW score ≤2). Total number of wounds decreases over time as closure is obtained.

At the following observation points (30th, 60th, 90th and 120th), due to the regression of the EGT, the COW score values

of the previous classified EGT Wounds (COW score >2) fell under SW classification (COW <2). Consequently during the proceed of the healing course, the previous EGT wounds were categorized as uncomplicated wounds (see figure 1).

The Initial Wound Area (IWA) of the SW group varied from a mean of 12,72±6.48 cm² (<25 cm² sub-group: n 14), 50,76±14,20 cm² (25-100 cm² sub-group: n 8) and 310,023±132,26 cm² (>100cm² sub-group: n 6) (size of 4 wounds were not determined) and from 12,90±4,51cm² (<25 cm² sub-group: n 17) to 62,76±26,55 cm² (25-100 cm² sub-group: n 7) (1 wound size was not determined) for the EGT-W group. No significant differences towards the analysed parameters (TTH, SER, HOW score, TFE and CAS) were observed between EGT-W B(bandaged) and EGT-W NB (not bandaged) subgroups therefore the healing parameters of the aggregated EGT-W group were compared with SW group.

The TTH demonstrate that SW healed faster than EGT-W. The mean of the TTH was 58,06±39,44 days for the SW group and 79,0±54,32 days for the EGT-W group (T=-2,57; df=44, p<0,01) while the TTH of the relative sub-groups were 40,14±26,44 days, 53,63±29,28 days and 104±48,49 for the <25cm², 25-100cm² and >100cm² SW sub-groups respectively and 56,18±28,40 and 134,0±64,04 days for the <25cm², 25-100cm² EGT-W sub groups respectively. Differences between the SW and EGT-W sub-groups <25cm² were not significant (T=-1,561; df=29 n.s.), while the differences between SW and EGT-W sub- groups 25 to 100cm² were significant (T=-2,98; df=13, p< 0,01) (see Table 2).

Table 2. Results of healing parameters (TTH and SER) and relative statistical analysis of SW and EGT-W groups.

TTH (days)			SER (cm/day)				
IWA	SW	EGT-W	Statistic	IWA	SW	EGT-W	Statistic
<25cm ²	40,14±26,44 (n.= 14)	56,18±28,40 (n.= 17)	T=-1,561 df=29 n.s.	<25cm ²	0,11±0,06 (n.= 14)	0,08±0,04 (n.= 17)	T=1,91; df=29 p<0,05
25-100cm ²	53,63±29,28 (n.= 8)	134±64,04 (n.= 7)	T=2,98df=13, p< 0,01	25-100cm ²	0,16±0,07 (n.= 8)	0,07±0,02 (n.= 7)	T=3,361; df=13 p<0,01
>100cm ²	104±48,49 (n.= 6)			>100cm ²	0,19±0,08 (n.= 6)		
Total	58,06±39,44 (n.= 28)	79±54,32 (n.= 24)	T=2,57df=44, p<0,01	Total	0,14±0,06 (n.= 28)	0,074±0,034 (n.= 24)	T=3,63; df=44 p<0,01

The healing parameter SER ($\sqrt{IWA/TTH}$ cm/day) confirmed that SW healed faster than the EGT-W. The SER of the SW group was 0,14±0,06 cm/day when calculated as total SW group and 0,11±0,06 cm/day, 0,16±0,07 cm/day and 0,19±0,08 cm/day for the <25cm², 25-100cm² and >100cm² SW sub groups respectively. The SER of the EGT-W group was 0,0742±0,0342 cm/day when calculated as total EGT-W group and 0,08±0,04 cm/day and 0,07±0,02 cm/day for the <25cm², 25-100cm² EGT W sub groups respectively. Statistical analysis showed significant differences between SW and EGT-W when the total groups (T=3,63; df=44 p<0,01) and relative sub groups (<25cm²: T=1,91; df=29 p<0,05) (25-100cm²: T=3,361; df=13 p<0,01) were compared (see Table 2).

The HOW score showed that the majority of the SW reached a healthy wound state during the first week of treatment (0 to 7 days: Z=2.37, P=0.018), whereas the

majority of the EGT-W achieved it during the second week (7 to 15 days: Z=2.61, P=0.009). At the 30th day all wounds presented a healthy wound state and during the whole remaining period, no clinical signs of infection were observed, not even in those wounds in which bone was exposed (n= 3 see Table 1).

A particular clinical observation was made in the cases of the EGT-WB sub-group. It showed a regression of the EGT associated, at the daily medication, with a self-limiting bleeding phenomenon which persisted until complete epithelialisation, without presenting clinical signs of inflammation, necrosis or infective complications. When the bandage accidentally slipped down, the exposed wound area presented fresh EGT formation, protruding above the skin level. Re-applying the bandage correctly, resulted in the hypergranulation resolving itself and the reappearance of the bleeding phenomenon at the dressing removal. The

EGT-WNB sub-group presented, during the whole healing course, a slight permanent protrusion of the granulation tissue (inferior to 0,3-0,5 cm) but bleeding was never observed. No trimming of granulation tissue was necessary.

The TFE occurred significantly sooner in the SW group compared to the EGT-W group (median of 7 days vs median of 18 days respectively) (Chi square=6.39 P=0.011).

The CAS showed that the SW and EGT-W Bandaged groups had comparable results of excellent scar quality (SW 87,5% and EGT-W 72%) (p<0,05) (see Figure 2). Even though the differences between EGT-WB and EGT-WNB were not significant, the EGT-WB presented a better CAS performances than the EGT-WNB (see figure 3). The eschar was always thin or absent in the SW group and EGT-W B sub-groups, while it was present in the EGT-W NB sub-group.

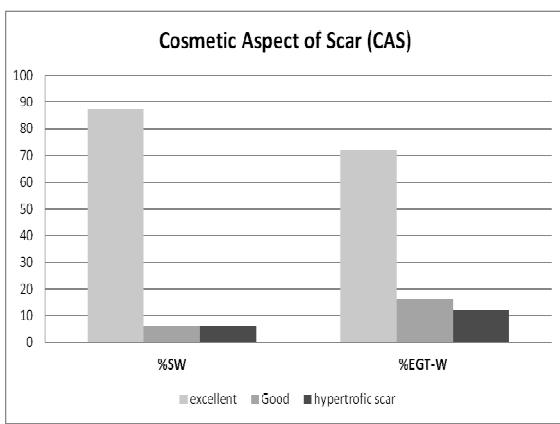


Figure 2. Histogram of the Cosmetic Aspect of the final Scar (CAS) expressed as percentage of the total number of wounds (%) for the SW group (n=32), the EGT-W (n= 25). Differences are not significant.

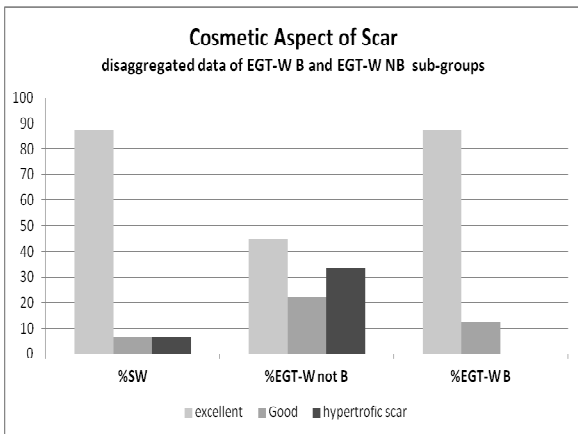


Figure 3. Histogram of the Cosmetic Aspect of the final Scar (CAS) expressed as percentage of the total number of wounds (%) for the SW group (n=32), the EGT-WNB (n= 10) and the EGT-WB (n= 16) (disaggregated data of EGT-W). Differences are not significant.

4. Discussion

When treating equine wounds, the primary goal is to obtain rapid wound closure with a functional and aesthetically satisfactory outcome. Dressings are used to enhance and support the healing process by decreasing contamination,

oedema and exudate, protecting against movement and further trauma and optimizing moisture, temperature, pH and gaseous exchanges at the wound site [24]. Dressing selection is too often based on habit or economics rather than scientific data, because there has been little research on the specific needs of equine wounds [20].

We are presenting a plant derived primary dressing for wounds that are intended to heal by secondary intention. Prior clinical evidence obtained in other animal/human models had shown that the device was effective as a wound primary dressing [34,35,36,37]. Historically most of the research on second-intention healing in horses has focused on superficial full-thickness skin wounds having a small diameter (2,5cm) which are hardly representative of the accidental wounds commonly seen in clinical practice [30]. Creating a more traumatic and painful wound model for experimental studies would be difficult to justify ethically [2]. We retrospectively analyzed a case series of accidental wounds commonly found in equine veterinary practice. To ensure that the clinical assessments were objective and to assess the evolution and outcome of the wound healing treatment, we applied evaluation criteria and statistic analysis for comparative evaluation, commonly used in experimental equine wound healing (TTH, SER, COW and HOW score, TFE, CAS) [2,19,20,28,40] and commonly adopted in human medicine [35,36,37].

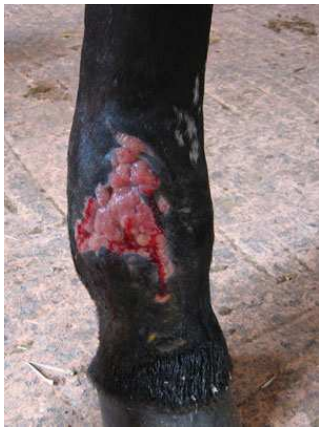Daily dressing was carried out without any apparent sign of procedural pain. It was easy and quick to apply. All of the horses accepted and became confident with the treatment without signs of fear or stress. The secondary dressing (when applied) did not stick to the wound surface and its daily removal never damaged the wound bed.

The TTH and the SER calculation showed that the wounds presenting with EGT heal slower than the simple wounds (SW), as first described by Stashak 1991 [1], confirming that EGT is responsible for the delay in the healing rate and in the appearance of the epithelium margin (TFE). Notwithstanding these differences, all of the wounds treated with the plant derived medical device underwent a healing process without any infective complication, also in absence of antibiotic intake. The treatment does not avoid the formation of the EGT at the 15th days after trauma on horses genetically predisposed to develop it, but does keep it under control over the whole following treatment period, especially when semi-occlusive bandaging is used, similarly to what is described by Ducharme-Desjarlais *et al.* 2005 [20] and Hackett R.P., 2011 [41] using silicone gel dressing. Differently to those studies, in this retrospective analysis, the trimming of the EGT was never necessary even though the trend to develop EGT during the time course was always present. In fact when the wound of the EGT-WB sub-group accidentally remained un-bandaged for some hours, the EGT formation started again on the residual wound surface. For re-obtaining the EGT regression and for avoiding the surgical trimming of the EGT, the application of the permanent semi-occlusive bandage in association with plant derived dressing was mandatory.

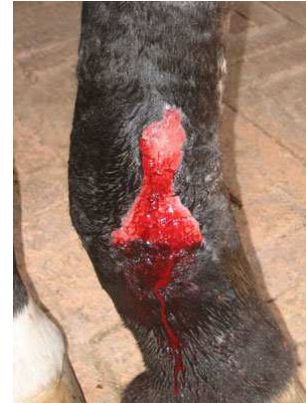Furthermore, the regressive effect on the EGT formation of

this protocol is demonstrated by the following COW score evaluations where it was observed that the percentage of the wounds presenting with EGT formation was drastically reduced during the whole time course of the wound healing (see Figure 1). The efficacy of the protocol on the EGT regression was always associated with a clinically recognizable bleeding phenomenon (see Figure 4, case N. W49 of Table 1). We interpret this “self-limiting bleeding phenomenon”, as the clinical sign of a physiological regression of the fibroblasts, without the involvement of the micro-vessel network which loses its blood contents and collapses upon the removal of the secondary dressing. This finding, that the combination of a plant derived primary dressing and semi-occlusive bandaging is beneficial for the EGT wound management, is contrary to what has been reported in the literature, where one of the major factors described as promoting the EGT is bandaging [1,2,6,14,15,16,17,19]. Similar to what Ducharme-Desjarlais et al. 2005 [20] and Hackett R.P, 2011 [41] reported about the silicone gel dressing, which favours cellular apoptosis and thus expediting wound repair in horses without EGT

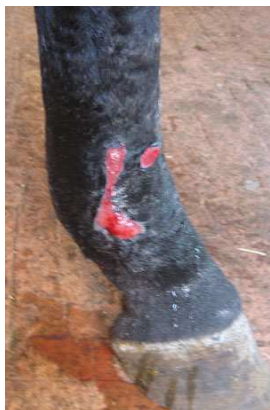formation, we postulate that such a mechanism is in play when our protocol is used in wounds at risk of strong and lasting EGT formation. Thus, it seems that bandaging is not the real cause of the EGT, but it could play a beneficial role if the primary dressing is effective in providing a moist wound environment and avoiding infective complications [20,40,41]. Furthermore, the promotion and maintenance of an optimal moist environment on the wound surface [40], as obtained in this study, could play an important role for avoiding the accumulation of the wound exudate which is recognized as promoting the EGT formation [3]. Contrary to what is reported about micro-vessel occlusion, as a concomitant cause of the EGT at the horse’s limb [4], in this study the EGT micro-vessel network showed itself to be functioning perfectly, as evidenced by the self-limiting phenomenon of bleeding (see Figure 4). We hypothesize that the superficial compression exercised on the vascular network at the wound surface, by the permanent semi-occlusive bandaging, could play a positive role to induce the superficial anoxia which is known to induce apoptosis of the proliferative fibroblasts [20].



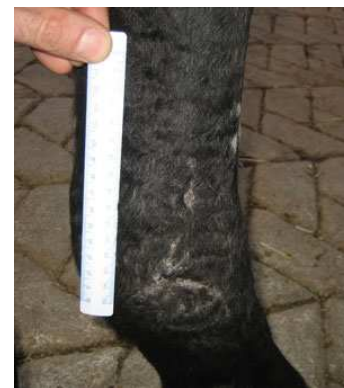Day 15 from trauma: aspect of the wound presenting with EGT formation



Day 45 from trauma: area reduction, regression of the EGT formation and presence of the bleeding phenomenon on the wound surface

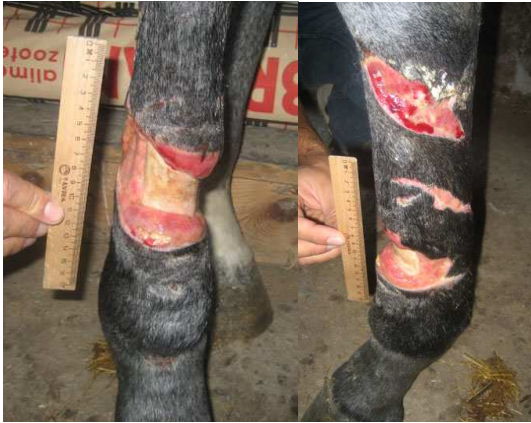

Day 90 from trauma: area reduction and EGT regression

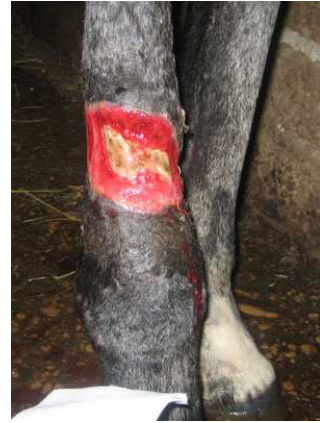

5 months from trauma: cosmetic aspect of the final scar

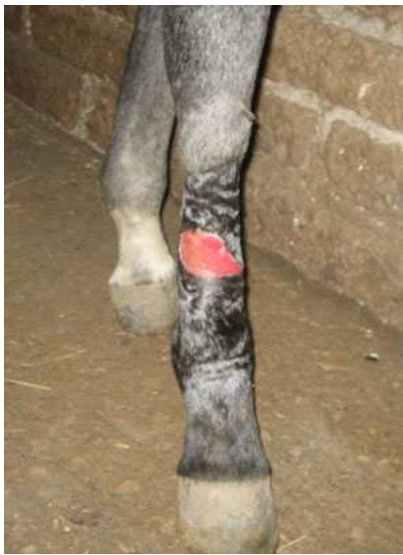Figure 4. Case N. W49. bleeding phenomenon at the secondary dressing removal and cosmetic aspect of final scar on wound presenting with EGT formation.



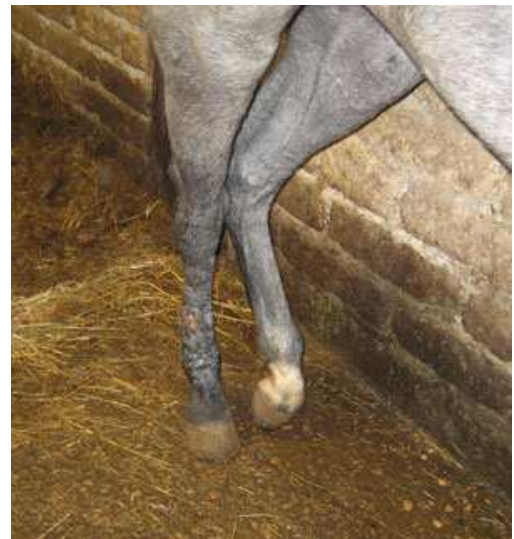Day 7 from trauma: front and lateral aspect of the wound with exposed bone at the front right cannon



Day 25 from trauma: partial covering of the exposed bone by granulation tissue

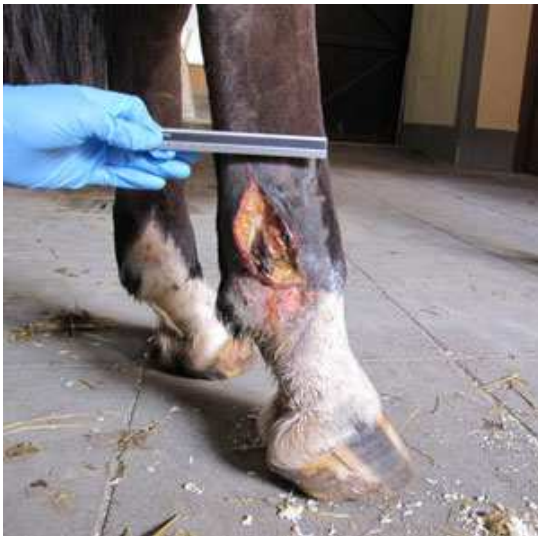

Day 40 from trauma: complete covering of the exposed bone

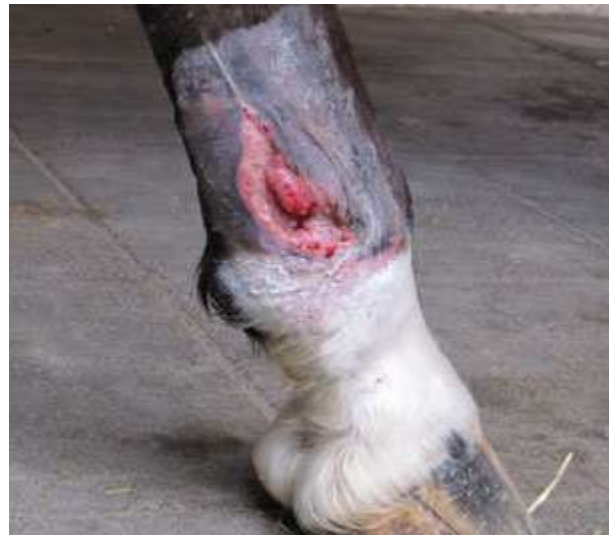

5 months after trauma: cosmetic aspect of the final scar. Cannon profile and dimension is similar to the contralateral

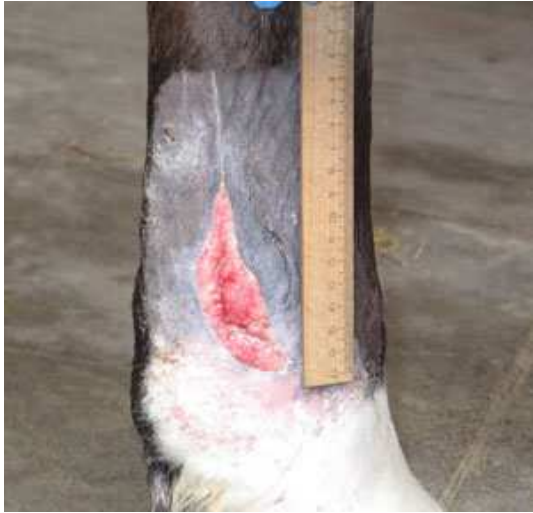Figure 5. Case N. W 56. Traumatic wound at the cannon bone with exposed bone



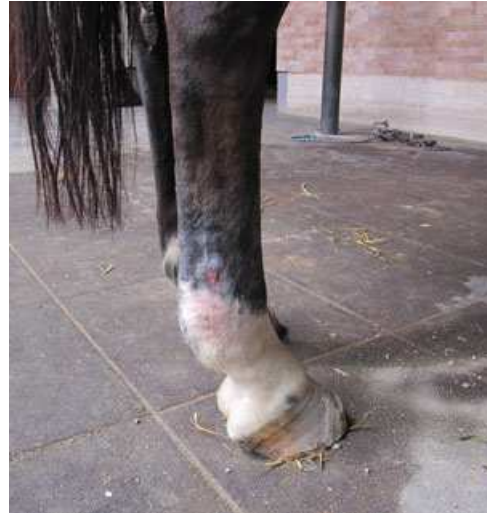Day 7 from trauma: small part of traumatized tissue are present, small clefts of EGT are visible



Day 15: wound bed is filled by EGT formation

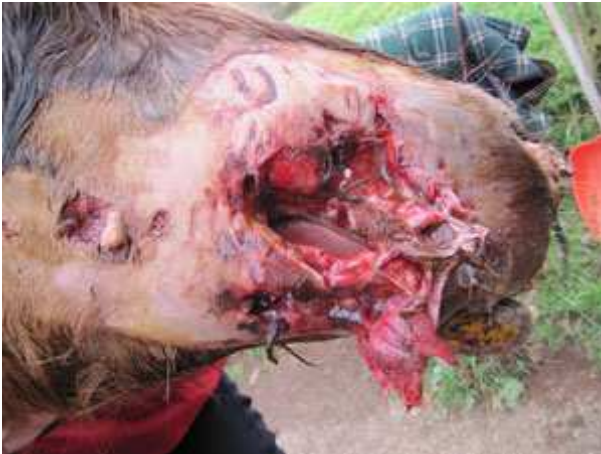

Day 21: regression of the EGT and wound area reduction

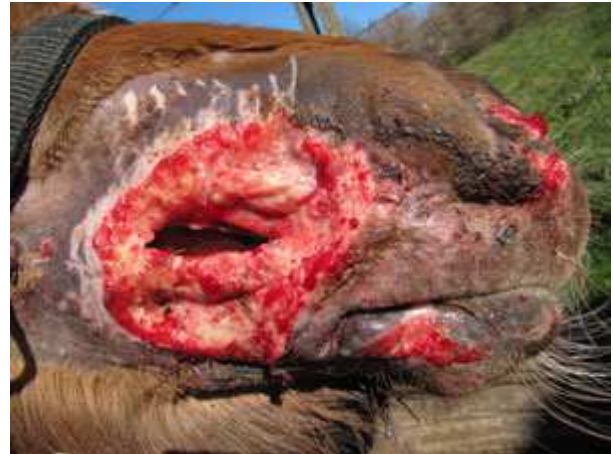

3months after trauma: cosmetic aspect of the final scar

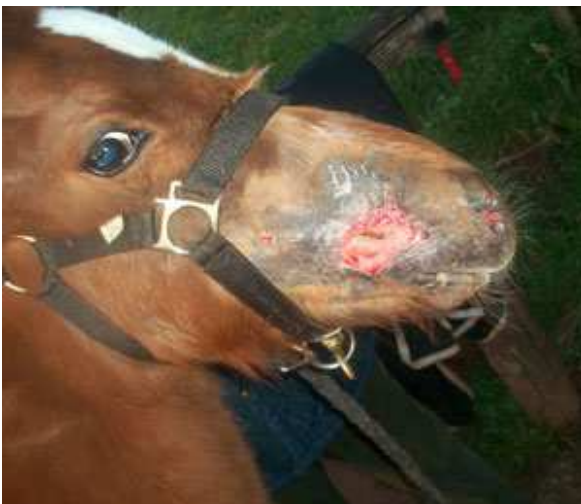Figure 6. Case N. W53. Traumatic wound at final aspect of posterior right cannon



Day 1 from trauma: Aspect of the wound. The lateral aspect of the tongue is visible.



Day 15: impressive formation of healthy granulation tissue and wound area reduction



Day 21: impressive wound area reduction and closure of the initial cheek laceration



Day 60: aspect of the final scar

Figure 7. Case N. W14. Traumatic bite wound with severe laceration of the cheek in a six months foal

Also the CAS score demonstrated the beneficial effects of the bandaging on EGT-W (see Figures 5, case N. W56 of Table 1 and Figure 6, case N. W53 of Table 1), even though the quality of the final scar between EGT-WB and EGT-WNB was comparable, the EGT-WNB sub-group presented the worse quality of scars (see Figure 3). Severity of scarring in horses is related to both a protracted inflammatory phase and an excessive fibroblastic phase, in which proliferative and synthetic fibroblasts dominate rather than disappearing or differentiating into contractile myofibroblasts [3]. A possible explanation for the high quality of the scars we observed in the EGT-W group, especially in the EGT-W B is that the proliferative phase evolves without the usually reported dysregulated processes and no protracted inflammatory phase occurs. We hypothesize that the good health of wounds and high quality of the resulting scars we obtained in this study (see Figure 5 case, N. W56 of Table 1, Figure 6, case N. W 53 of Table 1 and Figure7, case N. W14 of Table 1) could also be strongly related to the avoidance of disinfectants/antimicrobials which are cytotoxic and/or cause oxidative damage to the cellular components, inhibiting or delaying epithelialisation and causing excessive scarring [40].

The possibility of not using these products, and at the same time limiting the intake of antibiotics for prolonged periods, avoiding any infective complications, may represent a novel modality for equine wound management with the added value of controlling EGT formation without the need of repeated surgical interventions, obtaining a high quality of final scar and limiting the onset of antibiotic resistance.

5. Conclusions

This retrospective non-controlled analysis confirmed that equine wound complicated by EGT have a lower healing performance. The plant derived medical device demonstrated perfect control of EGT formation without the need to perform repeated surgical trimming, while at the same time, obtaining a high quality of final scar. The treatment is an innovative medical device that can be applied on wounds from trauma till complete epithelialisation. There is no need to differentiate the treatment in function of the different healing phases, thus avoiding the use of multiple products and/or antimicrobial/disinfectant. It enables to reduce the intake of antibiotic and consequently limiting the risk of antibiotic resistance.

The treatment is simple to use and safe for all types of equine wound healing by secondary intention, also when in presence of large, severe and devastating wounds that cannot be bandaged. For these cases, the repellent properties toward myiasigenic flies, reason for which the device was first invented, is of course, an important innovation.

Acknowledgements

The authors thank dr. Marcello Curcio, Erebo Menconi, Giorgia Cabianca and Francesco Putti for their veterinary

assistance, Tiziana Coccioletti and Oliviero Maccioni for technical assistance as well as dr. Alessandro Valbonesi and dr. Gemma Casadei for the statistical analysis provided.

References

- [1] Stashak TS. (1991) Principles of wound healing. In: Stashak TS ed. *Equine Wound Management*. First Edition pp 1-18.
- [2] Dart AJ Perkins NR, Dart CM, Jeffcott LB and Canfield P (2009) Effect of bandaging on second intention healing of wounds of the distal limb in the horses. *Aust Vet J*,87(6), 215-218
- [3] Theoret CL and Wilmink JM. (2008) Treatment of Exuberant Granulation Tissue. In: Stashak TS ed. *Equine Wound Management*. Second Edition pp445-462.
- [4] Lepault E, Cèleste C., Doré M., Martineau D and Theoret C. (2005) Comparative Study on Microvascular Occlusion and Apoptosis in Body and Limb Wounds in the Horse. *Wound Rep Reg*, 13, 520-529.
- [5] Miller CB, Wilson DA, Keegan KG, Kreger JM, Adelstein EH and Ganjam VK. (2000) Growth characteristics of fibroblasts isolated from the trunk and distal aspect of the limb of horses and ponies. *Vet Surg*, 29,1-7.
- [6] Fretz PB, Martin GS, Jacobs KA et al. (1983) Treatment of exuberant granulation tissue in the horse: evaluation of four methods. *Vet Surg*, 12, 137-140.
- [7] Cochrane CA, Pain R and Knottenbelt DC. (2003). In-vitro wound contraction in the horse: differences between body and limb wounds. *Wounds*, 15(6), 175-181.
- [8] Theoret CL, Barber SM, Moyana TN and Gordon JR. (2001) Expression of transforming growth factors 1, 3 and basic fibroblast growth factor in full-thickness skin wounds of equine limbs and thorax. *Vet Surg* 30,269-277
- [9] van den Boom R, Wilmink JM, O’Kane S, Wood J and Ferguson MW. (2002) Transforming growth factor-beta levels during second-intention healing are related to the different course of wound contraction in horse and ponies. *Wound Rep Reg*, 10, 188-194.
- [10] Wilmink JM, Veenman JN, van den Boom R, Ratten VP, Nievoeld TA, Broekhuisen-Davies JM, lees R, Armstrong S van Weeren PR and Barneveld A. (2003) Differences in polymorphonucleocyte fuction and local inflammatory response between horses and ponies. *Equine Vet J*; 35, 561-569.
- [11] Cochrane C. (1997) Models in vivo of wound healing in the horse and the role of growth factors: *Vet Dermatol*, 8, 259-272.
- [12] Miragliotta V, Raphae K, Ipin Z, Lussier JG and Theoret CL. (2009) Equine thrombospondin II and secreted protein acidic and cysteine-rich in a model of normal and pathological wound repair. *Physiol Genomics* 38, 149–157.
- [13] Knottenbelt DC. (1997) Equine wound management: are there significant differences in healing at different sites on the body? *Vet Dermat*; 8, 273-290.
- [14] Hendrickson D and Virgin J. (2005) Factors that affect equine wound repair. *Vet Clin Equine*, 21,33-44.

- [15] Gomez JH, Hanson RR. (2005) Use of dressing and bandages in equine wound management. *Vet Clin North Am* 21,91-104.
- [16] Barber SM. (1989) Second intention wound healing in the horse: the effect of bandages and topical corticosteroids. In: Proceedings 35th Annu Meet *Am Assoc Equine Pract*, 107-116.
- [17] Bertone AL. (1989b) Management of Exuberant Granulation Tissue. In: Booth LC ed. Wound management. *Vet. Clin North Am Equine Pract*. Philadelphia: WB Saunders Company, 5,551-562.
- [18] Howard RD, Stashak TS, Baxer GM. (1993) Evaluation of occlusive dressing for management of full-thickness excisional wounds on distal portion of the limbs of horses. *Am J Vet Res* 54, 2150-2154.
- [19] Berry D and Sullins KE. (2003) Effects of topical application of antimicrobials and bandaging on healing and granulation tissue formation in wounds of the distal aspect of the limbs in horses. *Am J Vet Res*, 64(1), 88-92.
- [20] Ducharme-Desjarlais M, Cèleste CJ, Lapault E and Theoret CL. (2005) Effect of silicone-containing dressing on exuberant granulation tissue formation and wound repair in horses. *Am J Vet Res*, 66, 1133-1139.
- [21] Azari O, Mahdi Molaei M and Hojabri R. (2010) Differences in second-intention wound healing of distal aspect of the limb between Caspian miniature horses and donkeys: macroscopical aspects. *Comp Clin Pathol* on line publications ©Springer-Verlag London Limited-2010 DOI 10.1007/s00580-010-1166-3.
- [22] Ghamsari SM, Azari O, Dehghan MM. (2007) Similarities of second intention wound healing between TB and Caspian miniature horses: macroscopical aspects. 10th *Annual Scientific Meeting*, November 15, Berlin, Germany, pp 31.
- [23] Knottenbelt DC. (2003a) Handbook of equine wound management. *Elsevier Science*, Sunders. pp. 5-23.
- [24] Knottenbelt DC. (2003b) Handbook of equine wound management. *Elsevier Science*, Sunders. pp. 39-77.
- [25] Wilmink JM. (2009) Chronic Exuberant Granulation Tissue-Any difference with "Regular" proud Flesh?. *Large Animal: Equine- NAVC Conference* 18-19.
- [26] Hanson RR. (2009) Complication of equine wound management and dermatologic surgery. *Vet Clin Equine*, 24, 663-696.
- [27] Stashak TS and Farstvedt E. (2008) Update on Wound dressing: indication and best use. In: Stashak TS ed. *Equine Wound Management*. Second Edition, pp 109-136.
- [28] Silveira A., Arroyo LG, Trout D, Moens NMM, LaMarre J and Brooks A. (2010) Effects of unfocused extracorporeal shock wave therapy on healing of wounds of the distal portion of the forelimb in horses. *Am J Vet Res*, 71, 229-234.
- [29] Sanchez AR, Sheridan PJ and Kupp LI. (2003) Is platelet-rich plasma the perfect enhancement factors? A current review. *Int J Maxillofac Implants*, 18, 93-103.
- [30] Wilmink JM and van Weren R. (2004) Differences in wound healing between horses and ponies: application of research results to the clinical approach of equine wounds. *Clin Tech Equine Pract*, 3, 123-133.
- [31] Thomas GW, Rael LT, Bar-Or R, Shimonkevitz R, Mains CV, Slone D.S, Craun ML and Bar-Or D. (2009) Mechanisms of delayed wound healing by commonly used antiseptics. *J Trauma*, 66(1), 82-90.
- [32] Atiyeh B.S., Dibo S.A. and Hayek S.N. (2009). Wound cleansing, topical antiseptics and wound healing. I. *Wound J* 6, 420-430
- [33] Stashak TS, Farstvedt E, Othic A. (2004) Update on wound dressing. *Clin Tech Equine Pract*, pp 148-163.
- [34] van der Esch SA, Carnevali F and Cristofaro M. (2007) Mix 557: A topical Remedy with repellent, biocidal and healing properties for treating Myiasis both in Mammal as in Human. *Proceeding EWMA*, Glasgow.
- [35] Lauchli S. (2012) 1 Primary Wound Dressing®: clinical experience. A novel wound dressing, formulated from natural oils, promotes effective healing, protects periwound skin and leads to an impressive induction of granulation tissue, even in deep wounds. *HHE* 1-3.
- [36] Lauchli S, Hafner J., Wehrman C., French L.E. and Hunziker T. (2012) Post-surgical scalp wounds with exposed bone treated with a plant derived wound therapeutic. *J. W. C.*, 21, 228-233.
- [37] Mainetti S and Carnevali F. (2013) An experience on pediatric burn wounds treated with a plant-derived wound therapeutic. *JWC*, 22, 12: 681-689; [38] Desbois AP and Smith VJ. (2010) Antibacterial free fatty acids: activities, mechanisms of action and biotechnological potential. Mini-Review. *Appl Microbiol Biotechnol*, 85, 1629-1642.
- [38] Drake DR, Brogden KA, Dawson DV and Wertz PW. (2008) Antimicrobial lipids at the skin surface. *J Lipid Res*, 49, 4-11.
- [39] Ketzner KM, Stewart AA, Byron CR, Gaughan EM, Vanharreveld PD and Lillich Jd. (2009) Wounds of the pastern and foot region managed with phalangeal casts: 50 cases in 49 horses (1995-2006). *Austr Vet J*, 87 (9), 368.
- [40] Stojadinovic A, Carlson JW, Schultz GS, Davis TA, Elster EA (2008) Topical advances in wound care. *Gynecologic Oncology* 111, S70-S80;
- [41] Hackett R. P. (2011) How to Prevent and Treat Exuberant Granulation Tissue AAEP PROCEEDINGS _ Vol. 57; 367-373-